

# Bonopty<sup>®</sup>

## Bone Biopsy System

### Procedural Information

Location: Washington, DC, USA  
Hospital: Washington Hospital Center  
Physician: C Logie, MD  
S. Dziedzic, MD  
J. Jelinek, MD

Clinical Case Review 10

## Percutaneous biopsy of an intramedullary femoral lesion

### Case Description

#### Case history

56 year old male with a painful medial femoral condyle chondroid lesion.

#### Biopsy details

The lesion was located within the medial femoral condyle. Using Bonopty<sup>®</sup> 12G Penetration Set (art no 12-1272), the lesion was approached posteromedially, adjacent to the insertion of deep fibers of the medial collateral ligament. The lesion was then sampled using Bonopty<sup>®</sup> 13G Biopsy Set (art no 12-1273).

#### Analysis of the samples

The lesion was successfully sampled without violation of the planned resection plane. Enchondroma was confirmed.

#### Comments

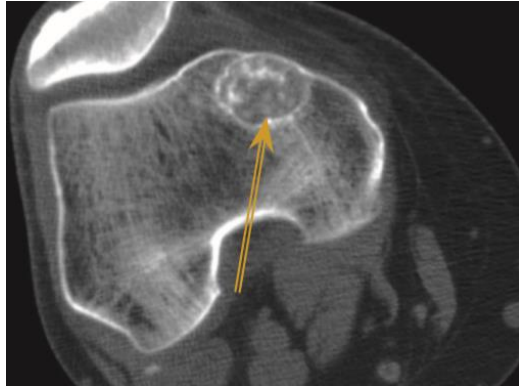
The large sample obtained by the 13 gauge biopsy needle enabled optimal histopathologic analysis of the equivocal chondroid lesion.

# Bonopty®

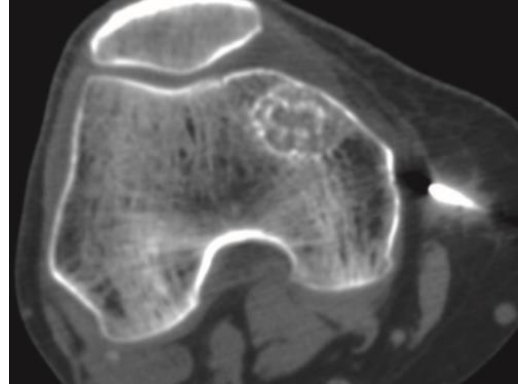
## Bone Biopsy System

### Clinical Case Review 10

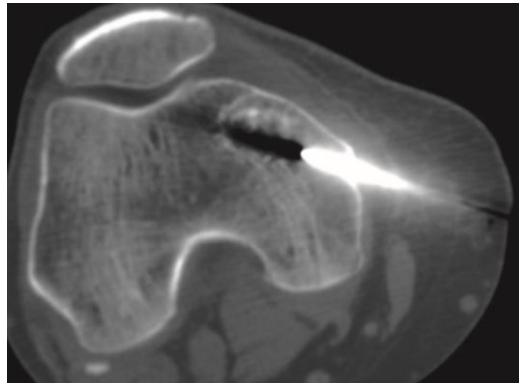
## Percutaneous biopsy of an intramedullary femoral lesion



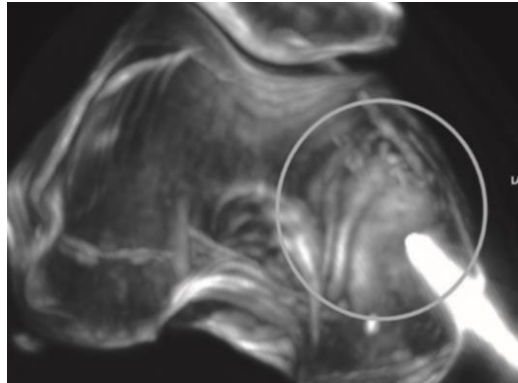
Geographic 1A lesion at the medial femoral condyle with chondroid matrix.



Bonopty® 12G Penetration Set advanced into soft tissue.




Bonopty® 12G Penetration Set further advanced, prior to removal of inner stylet.



3D MIP reconstruction of the posteromedial approach using Bonopty®.

Case and image courtesy of C Logie, MD; S. Dziejcz, MD; J. Jelinek, MD; Washington Hospital Center, Washington, DC, USA.

[apriomed.com](http://apriomed.com)

 Biopsy of bone lesions. Before using Bonopty® Coaxial Bone Biopsy System read the instructions for use which accompany the product for indications, contraindications, warnings and precautions. Bonopty® is a registered trademark of AprioMed AB. Patents pending.

**AprioMed** 