

Procedural Information

Location: Marshfield WI, USA
Hospital: Marshfield Clinic
Physician: Eric Callaghan, MD

Clinical Case Review 7

Deep biopsy of lesion in L3

Case Description

Case history

54 year old male with a right lung mass and a single area of abnormal uptake on PET scan at L3.

Biopsy details

Lesion was located just over 13 cm from skin surface. L3 was accessed using Bonopty[®] Penetration set, 13 cm. Biopsy sample was obtained using Bonopty[®] Biopsy set, 19.5 cm.

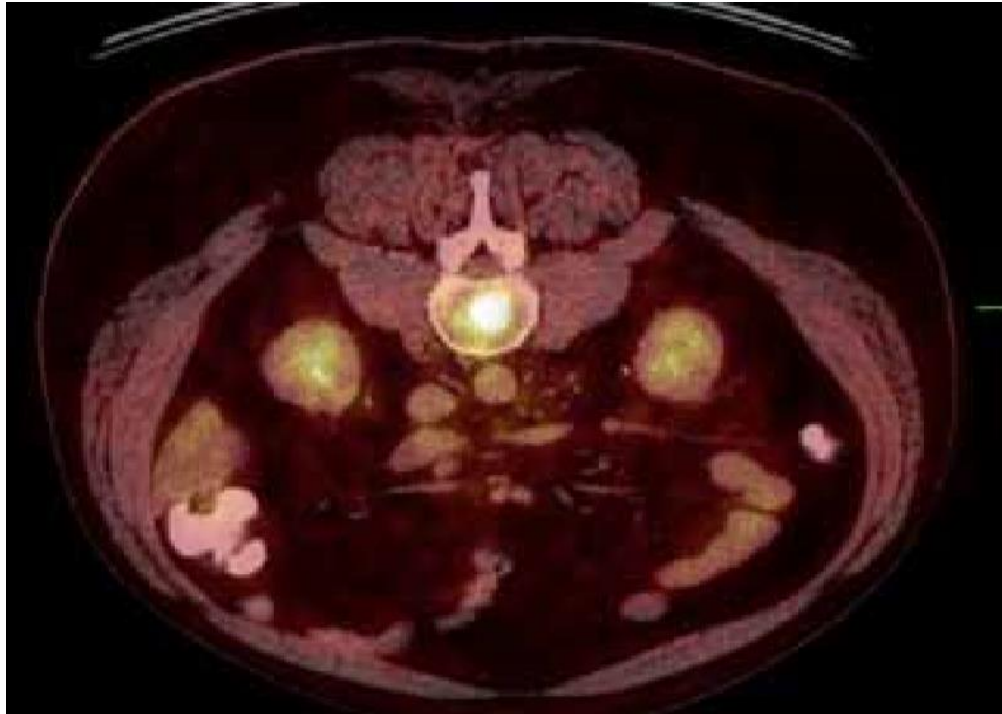
Analysis of the samples

Biopsy was successful and metastatic diagnosis was confirmed.

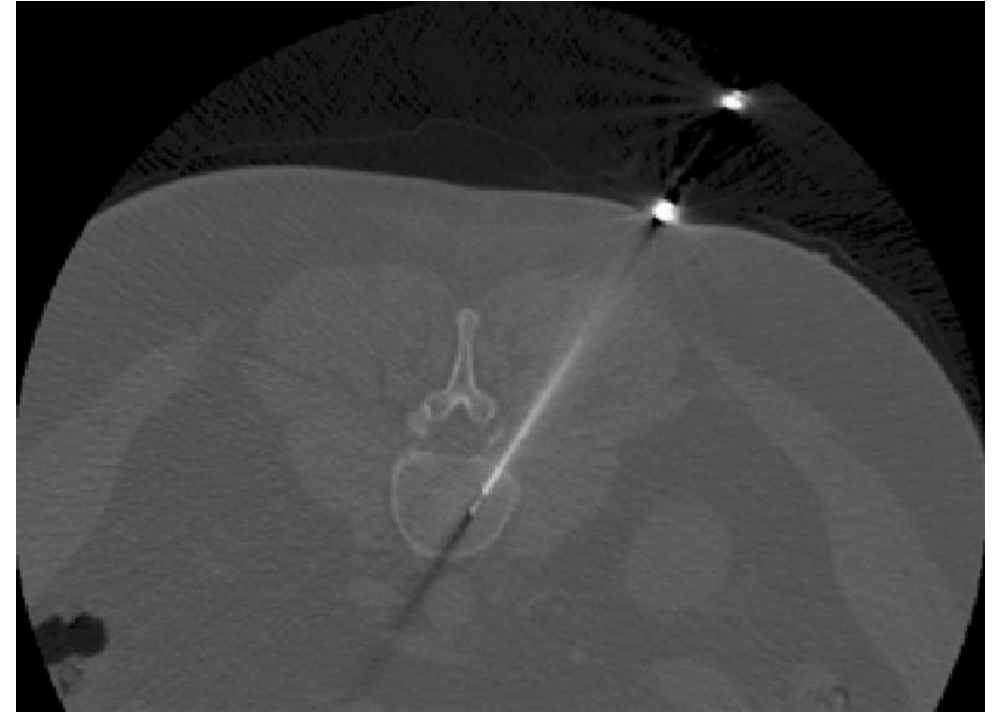
Comments

The longer Bonopty[®] Penetration set (art no 10-1082) and Bonopty[®] Biopsy set (art no 10-1083) allowed for further reach of the lesion, which might have been inaccessible with standard size Bonopty[®] Penetration set (art no 10-1072) and Bonopty[®] Biopsy set (art no 10-1073).

Deep biopsy of lesion in L3



PET CT showing lesion at L3 suspicious for metastatic disease.



Extra long Bonopt[®] core retrieval advanced.

Case and image courtesy of Eric Callaghan, MD Marshfield Clinic, Marshfield WI, USA.