

# Support during superficial puncture

## Procedural Information

Location: Marshfield WI, USA  
Hospital: Marshfield Clinic  
Physician: Eric Callaghan, MD

## Case Description

### Case history

46 year old male with a mass in his lateral gastrocnemius. Initial diagnosis appeared to be hemangioma or a ganglion cyst.

### Biopsy Details

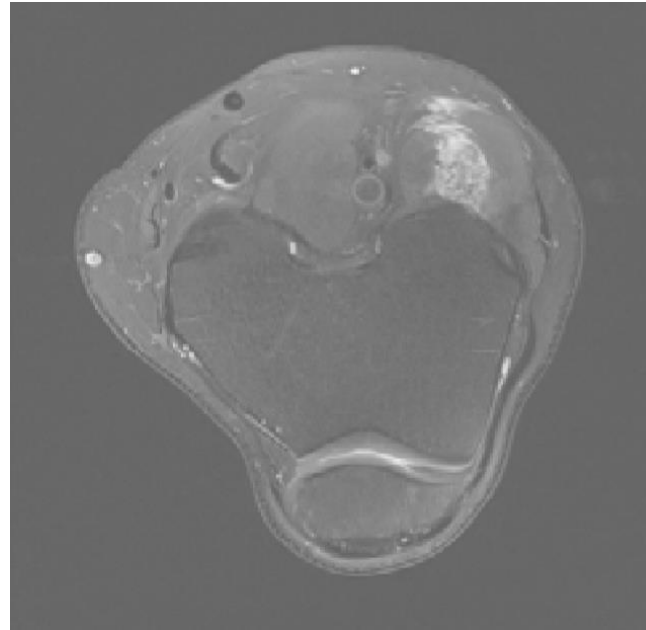
The lesion was less than 2 cm beneath the skin. SeeStar® (17G pink) anchored the coaxial 19G 6 cm needle. Several 20G core passes were made along with 22G FNA's.

### Analysis of the Samples

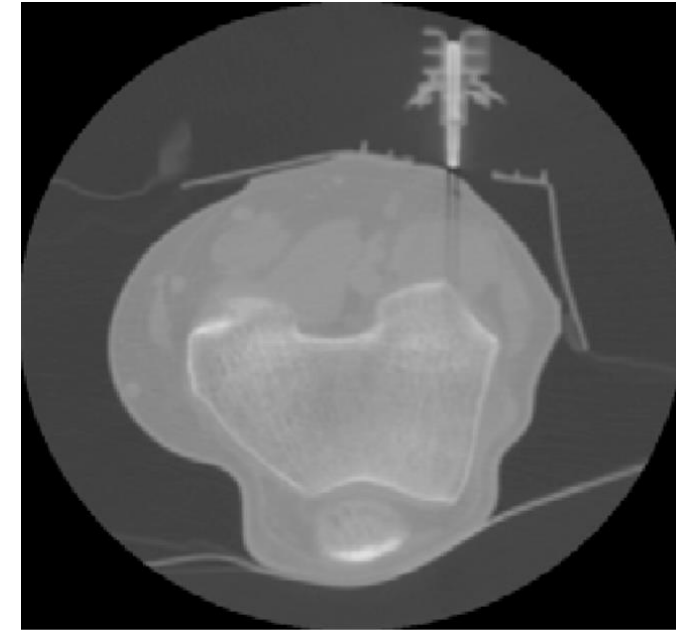
The pathology proved a ganglion cyst.

### Comments

The orthopedic oncologist prefers to biopsy most lesions with CT instead of ultrasound so he can visualize the needle track easier. Since the lesion was less than 2 cm beneath the skin, SeeStar® anchored the coaxial 19G 6 cm introducer needle.



Pre-procedure MRI



SeeStar® Localization