

# Bonopty®

## Sampling a lytic lesion: Lateral approach

### Case history

Lymphoma patient with suspected progressive disease.

### Biopsy details

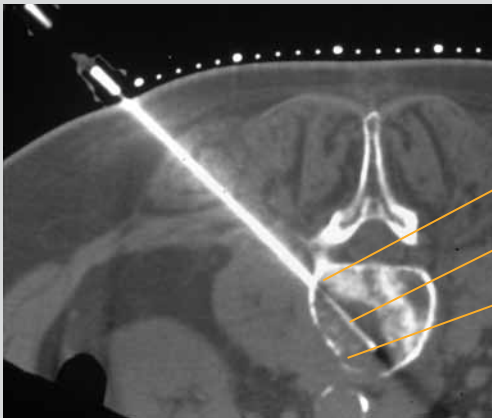
Biopsy samples were obtained through the anchored Bonopty® Penetration Cannula, with both Monopty® biopsy instrument (n=4) and Bonopty® Biopsy Cannula (n=1).

### Analysis of the samples

Five short samples were obtained, four of which showed areas of lymphoma. The best specimen was acquired with Bonopty® Biopsy Cannula, presumably due to partly intact bone content of the lesion.

### Comments

It was easy to exchange one biopsy sampling needle for another through the anchored Bonopty® Penetration Cannula.



### CT scan of the third lumbar vertebrae

Anchored Bonopty® Penetration Cannula

Bonopty® Biopsy Cannula

*Lytic lesion with bone structures*

#### Acknowledgements:

Courtesy of Dr K. Gunnar O. Åström and Dr K. Håkan Ahlström, Uppsala University Hospital.

#### Reference:

Åström K, Gunnar O., Sundström J. C., Lindgren P.G., Ahlström K Håkan:  
Automatic biopsy instruments used through a coaxial bone biopsy system with an  
eccentric drill tip: ACTA Radiologica 1995; 36: 237-242.

Bonopty® is a registered trademark of AprioMed AB, Sweden.